

Acute Abdominal Pain Pathway

Clinical Assessment/ Management tool for Children

Management - Primary Care and Community Settings

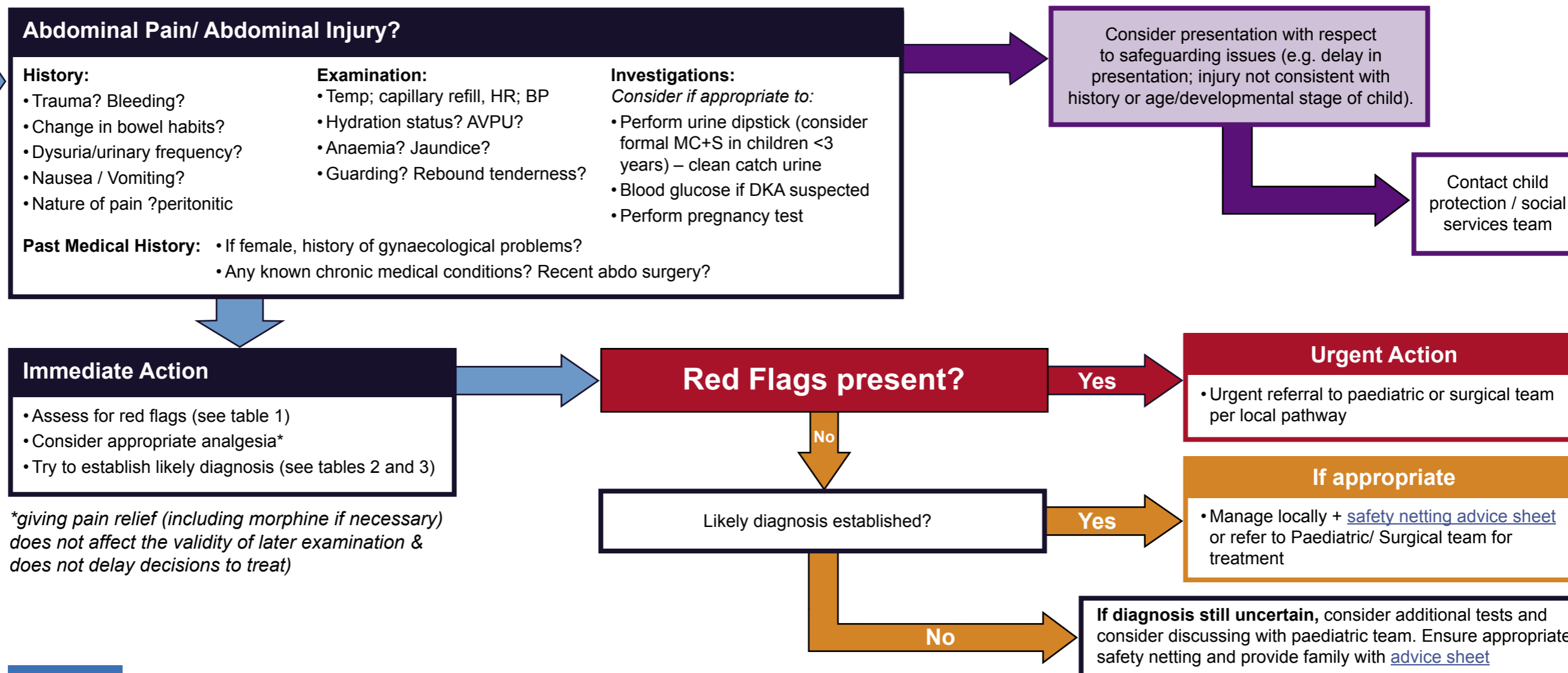


Table 1

Medical Red Flags	Surgical Red Flags	Red Flags (medical or surgical)
<ul style="list-style-type: none"> • Septic appearance (fever, tachycardia, generally unwell) • Respiratory symptoms (tachypnoea, respiratory distress, cough) • Generalised oedema - suspect nephrotic syndrome • Significant dehydration (clinically or >5% weight loss) • Purpuric or petechial rash (suspect sepsis meningococcal disease if febrile) • Jaundice • Polyuria / polydipsia (suspect diabetic ketoacidosis) 	<ul style="list-style-type: none"> • Peritonitis (guarding, rebound tenderness, constant dull pain exacerbated by movement) • Suggestion of bowel obstruction (colicky abdo pain, bilious vomiting, resonant bowel sounds) • History of recent significant abdominal trauma • History of recent abdominal surgery • Irreducible hernia • Testicular pain – consider torsion, esp after puberty • “Red currant jelly” stool 	<ul style="list-style-type: none"> • Severe or increasing abdominal pain • Blood in stool • Abdominal distension • Bilious (green) or blood-stained vomit • Palpable abdominal mass • Child unresponsive or excessively drowsy • Child non-mobile or change in gait pattern due to pain

GMC Best Practice recommends: Record your findings (See “Good Medical Practice” <http://bit.ly/1DPXI2b>)

First Draft Version: June 2016 Review Date: June 2018.

CS50218

Acute Abdominal Pain Pathway

Clinical Assessment/ Management tool for Children



Management - Primary Care and Community Settings

Table 2

Differential Diagnosis	Most important features
Gastroenteritis	Diarrhoea and / or vomiting, other family members affected
Infantile colic	Young healthy infant with episodes of inconsolable cry and drawing up of knees, flatus
Appendicitis	Fever, anorexia, migration of pain from central to RIF, peritonism (clinical or history suggestive), tachycardia, raised CRP (or CRP rise after 12 hours)
Mesenteric adenitis	High fever, pain often RIF and fluctuating severity. Concomitant or antecedent URTI. Generally occurs age 5-10 years. Can be hard to distinguish from appendicitis but no peritonism, site of pain typically not constant and child may be hungry. Far more common than appendicitis.
Intussusception	Mostly < 2 yrs, pain intermittent with increasing frequency, vomits (sometimes with bile), drawing up of knees, red currant jelly stool (late sign)
Meckel's diverticulum	Usually painless rectal bleeding. Symptoms of intestinal obstruction. Can mimic appendicitis
Constipation	Positive history. Pain mainly left sided/ supra pubic. If acute look for organic causes (ie obstruction)
UTI	Fever, dysuria, loin/ abdominal pain, urine dipstick positive for nitrites/ leucocytes – send formal MC+S if age < 3 years
Testicular torsion	More common after puberty. Sudden onset, swollen tender testis. No relief/ increase of pain after lifting testicle suggests torsion rather than bacterial epididymitis.
Irreducible hernia	Painful enlargement of previously reducible hernia +/- signs of bowel obstruction
HSP	Diffuse / colicky abdominal pain, non-blanching rash (obligatory sign), swollen ankles/ knees, haematuria/ proteinuria
HUS	Unwell child with bloody diarrhoea and triad of: anaemia, thrombocytopenia & renal failure
Lower lobe pneumonia	Referred abdominal pain + triad of: fever, cough and tachypnoea
Diabetic ketoacidosis	Known diabetic or history of polydipsia/ polyuria and weight loss, BM >15, metabolic acidosis (HCO ₃ <15) and ketosis
Sickle cell crisis	Nearly exclusively in black children. Refer to sickle cell disease guideline for differentiation with non-crisis causes
Trauma	Always consider NAI. Surgical review necessary
Psychogenic	Older child with excluded organic causes

Table 3

Female gynaecological pathologies	
Menarche	On average 2 yrs after first signs of puberty (breast development, rapid growth). Average age in UK is 13 yrs
Mittelschmerz	One sided, sharp, usually < few hours, in middle of cycle (ovulation)
Pregnancy	Sexually active, positive urine pregnancy test
Ectopic pregnancy	Pain usually 5-8 weeks after last period, increased by urination/ defaecation,. Late presentations associated with bleeding (PV, intra-abdominal)
Pelvic inflammatory disease	Sexually active. Risk increase with: past hx of PID, IUD, multiple partners. Fever, lower abdo pain, discharge, painful intercourse
Ovarian torsion	Sudden, sharp, unilateral pain often with nausea/ vomiting. Fever if necrosis develops

Glossary of Terms

ABC	Airways, Breathing, Circulation
APLS	Advanced Paediatric Life Support
AVPU	Alert Voice Pain Unresponsive
B/P	Blood Pressure
CPD	Continuous Professional Development
CRT	Capillary Refill Time
ED	Hospital Emergency Department
GCS	Glasgow Coma Scale
HR	Heart Rate
MOI	Mechanism of Injury
PEWS	Paediatric Early Warning Score
RR	Respiratory Rate
WBC	White Blood Cell Count